

New approach for T-shaped uterus: Metroplasty with resection of lateral fibromuscular tissue using a 15 Fr miniresectoscope. A step-by-step technique

U. CATENA¹, R. CAMPO², G. BOLOMINI¹, M.C. MORUZZI¹, V. VERDECCHIA¹, F. NARDELLI¹, I. ROMITO¹, F. CAMOLO¹, V. LA MANNA¹, M. M. IANIERI¹, G. SCAMBIA^{1,3}, A. C. TESTA^{1,3}

¹Department of Women's and Children's Health, Fondazione Policlinico Universitario "A. Gemelli"- IRCCS, Largo Francesco Vito 1, 00168, Rome, Italy; ²Department of Obstetrics and Gynecology, ZOL Hospitals, Genk, Belgium; ³Istituto di Ginecologia e Ostetricia, Università Cattolica del Sacro Cuore, Rome, Italy.

Correspondence at: Ursula Catena, Department of Women's and Children's Health, Fondazione Policlinico Universitario "A. Gemelli"- IRCCS, Largo Francesco Vito 1, 00168, Rome, Italy. Email: ursula.catena@gmail.com

Abstract

T-shaped uterus is a congenital uterine malformation (CUM), only recently defined by the ESGE ESHRE classification as Class U1a. The uterus is characterised by a narrow uterine cavity due to thickened lateral walls with a correlation 2/3 uterine corpus and 1/3 cervix (Grimbizis et al, 2013). Although the significance of this dysmorphic malformation on reproductive performance has been questioned, recent studies reported significant improvement of life birth rates after surgical correction in patients with failed in-vitro fertilisation (IVF) or recurrent miscarriage (Ferro et al, 2018; Di Spiezio Sardo et al, 2020; Alonso Pacheco et al. 2019). The classical surgical technique to treat a T-shaped uterus is by performing a sidewall incision with the micro scissor or bipolar needle, resulting in a triangular cavity.

In this video article, we describe a new surgical technique with a step-by-step method combining three-dimensional ultrasound (3D-US) and hysteroscopic metroplasty in an office setting, using a 15 Fr office resectoscope (Karl Storz, Tuttlingen, Germany), to treat a T-shaped uterus by resecting the lateral fibromuscular tissue of the uterine walls. No complications occurred and the postoperative hysteroscopy showed a triangular and symmetrical uterine cavity without any adhesions.

Key words: Hysteroscopy, T-shaped uterus, metroplasty, mini-resectoscope, dysmorphic uterus, three-dimensional ultrasound.

Introduction

Female genital malformations are defined as a deviation from normal anatomy due to an impaired development of the Mullerian or paramesonephric ducts. The incidence in the general population is around 0.2-0.4% (Byrne et al., 2000) while in the infertile population is around 4-13% (Grimbizis et al., 2001; Saravelos et al., 2008). Often, uterine malformations are associated with recurrent miscarriage (Grimbizis et al., 2013).

A new classification of uterine malformation was recently published with the collaboration of the European Society of Human Reproduction and Embryology (ESHRE) and the European Society for Gynaecological Endoscopy (ESGE). A new category

defined as "dysmorphic uterus" was introduced (Grimbizis et al., 2013). Recently, the Congenital Uterine Malformations by Experts (CUME) group has identified the best measurements that had good diagnostic test accuracy and fair to moderate inter-observer reliability/agreement. The best cut-offs values for these measurements were:

- lateral indentation angle $\leq 130^\circ$
- lateral indentation depth ≥ 7 mm
- T-angle $\leq 40^\circ$

They suggest considering as definitely T-shaped uterus when all three criteria are present. (Ludwin et al., 2019) (Figure 1).

Many studies reported poor reproductive outcomes when this malformation was present

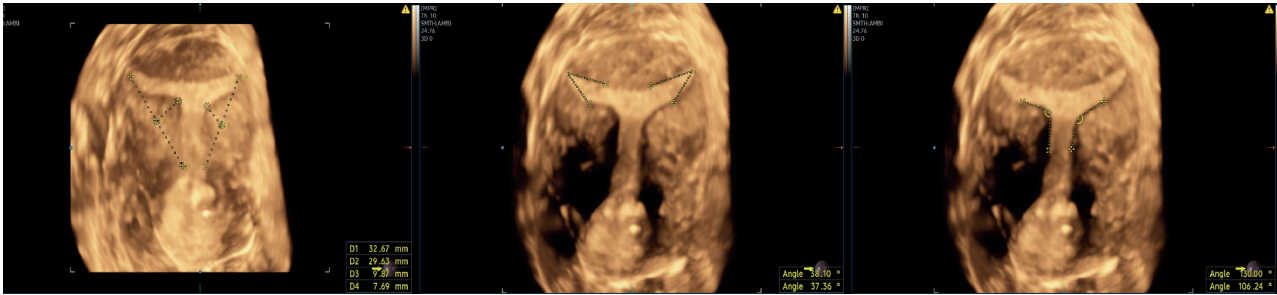

Figure 1: 3D-US diagnosis of T-shaped uterus, according to CUME consensus (Ludwin et al., 2019): the uterus showed: both lateral indentation depth ≥ 7 mm in size, bilateral T-angle $\leq 40^\circ$ and both lateral indentation angle $\leq 130^\circ$. No indentation was detected at fundus level.

(Di Spiezio Sardo et al., 2020). In 1992, Golan et al demonstrated an association between T-shaped uterus and a high rate of first-trimester miscarriage (47%) and a low rate of full-term delivery (21%) (Golan et al., 1992).

The management of such patients remain unclear because of the absence of standardised diagnostic criteria and lack of studies comparing surgical treatment with expectant management. Hysteroscopic treatment is often used, however, only few studies have been published evaluating the pregnancy outcome after surgical treatment (Ferro et al., 2018; Di Spiezio Sardo et al., 2020; Alonso Pacheco et al., 2019). Moreover, different surgical techniques have been proposed (Fernandez et al., 2000; Katz et al., 1996; Fernandez et al., 2011; Boza et al., 2019; Di Spiezio Sardo et al., 2016) and most of them included small sample size.

Recently, we have experienced a revolutionary change in our diagnostic and therapeutic approach by introducing the simultaneous use of three-dimensional ultrasound (3D-US) imaging and outpatient hysteroscopy both for the diagnosis and treatment of congenital uterine malformations (CUM). 3D-US imaging has already proved to be the gold standard in the diagnosis of CUM (Bermejo et al., 2010; Salim et al., 2003). Recent technological advances in hysteroscopy allowed gynaecologists to abandon the need for general anaesthesia and cervical dilation, making some procedures such as metroplasty feasible and safe in an “outpatient setting” (Bettocchi et al., 2007; Di Spiezio Sardo et al., 2010). In this new era, 3D-US could be successfully integrated within the endoscopic tower giving rise to the concept of a “digital hysteroscopic clinic” (DHC), where diagnostic and therapeutic moments are united in a one-stop clinic, as recently proposed by Campo (Campo et al., 2018).

In this video presentation, we describe a new surgical technique with a step-by-step method combining 3D-US and hysteroscopic metroplasty in an office setting, using a 15 Fr office resectoscope (Karl Storz, Tuttlingen, Germany), to resect the

lateral fibromuscular tissue of the uterine walls, removing the constriction rings in the isthmic area.

Methods

A 36-year-old woman was referred to our centre following suspicion of a uterine malformation. The patient’s medical history was positive for primary infertility and she underwent three failed in-vitro fertilisation (IVF) attempts. Diagnostic 30° hysteroscopy and 3D-US were performed. Diagnostic hysteroscopy showed a narrow uterine cavity due to thickened lateral walls. Transvaginal 2D ultrasound examination showed a small submucosal uterine myoma (G3) of 10 x 9 x 11 mm in size while both adnexa appeared regular. Using 3D software, the diagnosis of T-shaped uterus was made. According to CUME consensus (Ludwin et al, 2019), the uterus showed both lateral indentation angle $\leq 130^\circ$, both lateral indentation depth ≥ 7 mm in size and bilateral T-angle $\leq 40^\circ$. No indentation was detected at fundus level (Figure 1). Therefore, due to the fertility desire of the patient and the previous failed IVF attempts, an hysteroscopic metroplasty was proposed. A written informed consent was obtained from the patient before the procedure.

The patient underwent hysteroscopic metroplasty with a bipolar 15 Fr resectoscope in an office setting under conscious sedation (as achieved with i.v. midazolam 10 milligrams and fentanyl 100 micrograms), during the follicular phase immediately after the menstrual phase of the cycle. Metroplasty was performed using a vaginoscopic approach with a bipolar 15 Fr office resectoscope. Saline solution was used as distension medium. Once entered, the uterine cavity showed a tubular morphology. The endometrial mucosa appeared regular. A 90° angled bipolar cutting loop was used to resect the lateral fibromuscular tissue of the uterine walls, removing the constriction rings in the isthmic area, first on the right side. During the procedure, the G3 myoma previously described

by ultrasound examination was also removed. The incision depth was between 5 and 7 mm and it was determined on the basis of the loop larger diameter (3.5 mm). The incision depth decreased from the cranial to the caudal part of the uterus according to the indentation of the sidewalls determined by 3D-US. The same procedure was repeated on the left uterine wall. No complication occurred. The specimens were sent for histology examination with a diagnosis of endo-myometrium with large fibrotic component. At the end of surgery, the uterine cavity appeared triangular and symmetric. The procedure was ended by controlling any bleeding and by reducing the inflow pressure of the distension medium. At 3D coronal section, uterine cavity appear restored with a normal triangular shape (Figure 2).

After the first deprivation bleeding, postoperative hysteroscopic control showed a triangular and symmetric uterine cavity without any adhesions.

Discussion

In this article, we describe a new surgical technique with a step-by-step method combining 3D-US and hysteroscopic metroplasty in an office setting, using a 15 Fr office resectoscope (Karl Storz, Tuttlingen, Germany), to resect the lateral fibromuscular tissue of the uterine walls, removing the constriction rings in the isthmic area.

Different surgical techniques have been proposed to treat the T-shaped uterus. Şükür et al proposed a lateral metroplasty performed with conventional 26-Fr resectoscope and monopolar needle electrode (Şükür et al., 2018). Di Spiezio Sardo et al. proposed an hysteroscopic metroplasty performed with the HOME-DU (Hysteroscopic Outpatient Metroplasty to Expand Dysmorphic Uteri) technique, characterised by lateral and antero-posterior incisions on the constriction rings (Di Spiezio Sardo et al., 2015). This technique was performed using a 5-mm diameter continuous flow hysteroscope with an oval profile and a 30° fore oblique telescope and a 5 Fr bipolar needle to make the incisions. The same authors also suggested that longitudinal

lateral incisions may also be performed using 5 Fr scissors to cut the fibromuscular constriction rings (Di Spiezio Sardo et al., 2020). Ferro described the technique using the 5 French scissors to perform the lateral wall incision (Ferro et al, 2018).

Regarding the use of the miniresectoscope, it was already proposed to treat isthmocele (Casadio et al., 2019) and uterine septa (Fascilla et al., 2019). Indeed, the small diameter of the sheath allow entry into the uterine cavity without cervical dilatation and so without anatomical distortion of the defect. According to Fascilla et al., resectoscopic metroplasty was performed with uterine septum excision. In particular, they initially incise the septum using an “L-shape” bipolar electrode up to the fundal area. Then, the septum was longitudinally transected into 2 parts, forming 2 triangles on the anterior and posterior uterine walls, with the base on the fundus and the apex facing the internal cervical os. At the end of the procedure, using a 90° angled bipolar loop, they resected the 2 triangles in parallel, uninterrupted, long strips from the fundus to the apex (Fascilla et al., 2019).

Our surgical technique to treat the T-shaped uterus, combines the benefits of miniaturised instruments and bipolar energy. With the 15 Fr office resectoscope (Karl Storz, Tuttlingen, Germany) we directly entered the uterine cavity without cervical dilatation. We used a 90° angled bipolar cutting loop to completely resect the lateral fibromuscular tissue of the uterine walls, removing the constriction rings in the isthmic area. We believe that resection of the lateral fibromuscular tissue with a mini-resectoscope, instead of making a conventional incision using a bipolar electrode, diode laser or cold scissor, may result in better anatomical restoration of a triangular shaped uterine cavity. Thus, our described technique may be an option to perform a hysteroscopic enlargement metroplasty with the goal of restoring the uterine cavity to its normal size and volume. In our case, the anatomical postoperative outcome was assessed on 3D ultrasonography as satisfactory according to CUME consensus, with

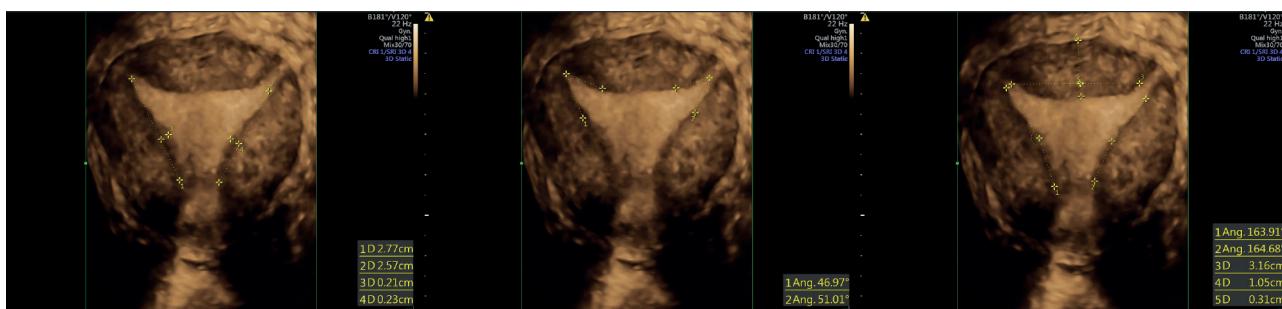


Figure 2: 3D-US postoperative control showed a regular uterine cavity. According to CUME consensus (Ludwin et al, 2019), the uterus had: both lateral indentation depth <7 mm in size, bilateral T-angle >40° and both lateral indentation angle >130°. No indentation was detected at fundus level.

a triangular shape cavity clearly apparent after the procedure (Ludwin et al., 2019), (Figure 2).

Whilst our study demonstrates the feasibility of a new approach adding to the existing literature pertaining to hysteroscopic metroplasty, it should be borne in mind that the evidence for reproductive benefit is scant. In the last three years, small, uncontrolled observational studies have been published demonstrating that hysteroscopic metroplasty in infertile patients with a T-shaped uterus may enhance reproductive outcomes (Ferro et al., 2018; Ducellier-Azzola et al., 2018; Di Spiezio Sardo et al., 2020; Alonso Pacheco et al., 2019). However, to date there is a lack of controlled observational or randomised studies evaluating the reproductive outcomes after hysteroscopic surgical treatment compared to expectant management. This uncertainty should be discussed with women with subfertility and a T-shaped uterus considering undergoing the procedure.

Conclusion

We propose a new surgical approach to treat the T-shaped uterus with a step-by-step method combining 3D-US and hysteroscopic metroplasty in an office setting, using a 15 Fr office resectoscope (Karl Storz, Tuttlingen, Germany). The small diameter of the sheaths makes the surgical procedure faster and easier compared with previous reported surgical procedures. This technique may allow the lateral fibromuscular tissue of the uterine walls to be completely removed while also removing the constriction rings in the isthmic area. It may also reduce the risk of complications, due to the vaginoscopic approach and the absence of cervical dilatation. Moreover, the use of 3D-US can guide the resection of the lateral fibromuscular tissue with a miniaturised bipolar cutting loop. Long term efficacy and safety of this new surgical technique should be confirmed by further studies before it may be offered as a routine treatment for the T-shaped uterus.

Video scan (read QR)

<https://vimeo.com/465700803/4ba8de0b78>



References

- Alonso Pacheco L, Laganà AS, Garzon S et al. Hysteroscopic outpatient metroplasty for T-shaped uterus in women with reproductive failure: results from a large prospective cohort study. *Eur J Obstet Gynecol Reprod Biol.* 2019;243:173-178.
- Bermejo C, Martinez Ten P, Cantarero R et al. Three-dimensional ultrasound in the diagnosis of Mullerian duct anomalies and concordance with magnetic resonance imaging. *Ultrasound Obstet Gynecol.* 2010; 35:593-601
- Bettocchi S, Ceci O, Nappi L et al. Office hysteroscopic metroplasty: three “diagnostic criteria” to differentiate between septate and bicornuate uteri. *J Minim Invasive Gynecol.* 2007;14:324-8.
- Boza A, Akin OD, Oguz SY et al. Surgical correction of T-shaped uteri in women with reproductive failure: Long term anatomical and reproductive outcomes. *J Gynecol Obstet Hum Reprod.* 2019;48:39-44.
- Byrne J, Nussbaum-Blask A, Taylor WS et al. Prevalence of Müllerian duct anomalies detected at ultrasound. *Am J Med Genet.* 2000;94:9-12.
- Campo R, Santangelo F, Gordts S, et al. Outpatient hysteroscopy. *Facts Views Vis Obgyn.* 2018; 10:115-22.
- Casadio P, Gubbini G, Morra C et al. Channel-like 360° isthmocele treatment with a 16 F mini-resectoscope: a step-by-step technique. *J Minim Invasive Gynecol.* 2019; 26: 1229-1230.
- Di Spiezio Sardo A, Bettocchi S, Spinelli M et al. Review of new office-based hysteroscopic procedures 2003-2009. *J Minim Invasive Gynecol.* 2010; 17:436-48.
- Di Spiezio Sardo A, Campo R, Zizolfi B et al. Long-term reproductive outcomes after hysteroscopic treatment of dysmorphic uteri in women with reproductive failure: an european multicenter study. *J Minim Invasive Gynecol.* 2020; 27:755-762.
- Di Spiezio Sardo A, Di Carlo C, Minozzi S et al. Efficacy of hysteroscopy in improving reproductive outcomes of infertile couples: a systematic review and meta-analysis. *Hum Reprod Update.* 2016; 22:479-496.
- Di Spiezio Sardo A, Florio P, Nazzaro G et al. Hysteroscopic outpatient metroplasty to expand dysmorphic uteri (HOME-DU technique): a pilot study. *Reprod Biomed Online.* 2015; 30:166-74.
- Ducellier-Azzola G, Lecointre L, Hummel M et al. Hysteroscopic enlargement metroplasty for T-shaped uterus: 24 years’ experience at the Strasbourg Medico-surgical and Obstetrical Centre (CMCO). *Eur J Obstet Gynecol Reprod Biol.* 2018.

- Fascilla FD, Resta L, Cannone R et al. Resectoscopic metroplasty with uterine septum excision: a histologic analysis of the uterine septum. *J Minim Invasive Gynecol.* 2019.
- Fernandez H, Garbin O, Castaigne V et al. Surgical approach to and reproductive outcome after surgical correction of a T-shaped uterus. *Hum Reprod.* 2011; 26:1730-1734.
- Fernandez H, Gervaise A, De Tayrac R. Operative hysteroscopy for infertility using normal saline solution and a coaxial bipolar electrode: a pilot study. *Hum Reprod.* 2000;15:1773-1775.
- Ferro J, Labarta E, Sanz C et al. Reproductive outcomes after hysteroscopic metroplasty for women with dysmorphic uterus and recurrent implantation failure. *Facts Views Vis Obgyn* 2018;10: 63-68.
- Golan A, Langer R, Neuman M et al. Obstetric outcome in women with congenital uterine malformations. *J Reprod Med.* 1992;37:233-236.
- Grimbizis GF, Camus M, Tarlatzis BC et al. Clinical implications of uterine malformations and hysteroscopic treatment results. *Hum Reprod Update.* 2001;7:161-174.
- Grimbizis GF, Gordts S, Di Spiezio Sardo A et al. The ESHRE/ESGE consensus on the classification of female genital tract congenital anomalies. *Hum Reprod.* 2013;28:2032-2044.
- Katz Z, Ben-Arie A, Lurie S et al. Beneficial effect of hysteroscopic metroplasty on the reproductive outcome in a 'T-shaped' uterus. *Gynecol Obstet Invest* 1996; 41:41-43.
- Ludwin A, Coelho Neto MA, Ludwin I et al. Congenital uterine malformation by experts (CUME): T-shaped uterus. *Ultrasound Obstet Gynecol.* 2019.
- Salim R, Woelfer B, Backos M et al. Reproducibility of three-dimensional ultrasound diagnosis of congenital uterine anomalies. *Ultrasound Obstet Gynecol.* 2003; 21:578-82.
- Saravelos SH, Cocksedge KA, Li TC. Prevalence and diagnosis of congenital uterine anomalies in women with reproductive failure: a critical appraisal. *Hum Reprod Update.* 2008;14:415-429.
- Şükür YE, Yakıştıran B, Özmen B et al. Hysteroscopic corrections for complete septate and T-Shaped uteri have similar surgical and reproductive outcome. *Reprod Sci.* 2018;25:1649-54.